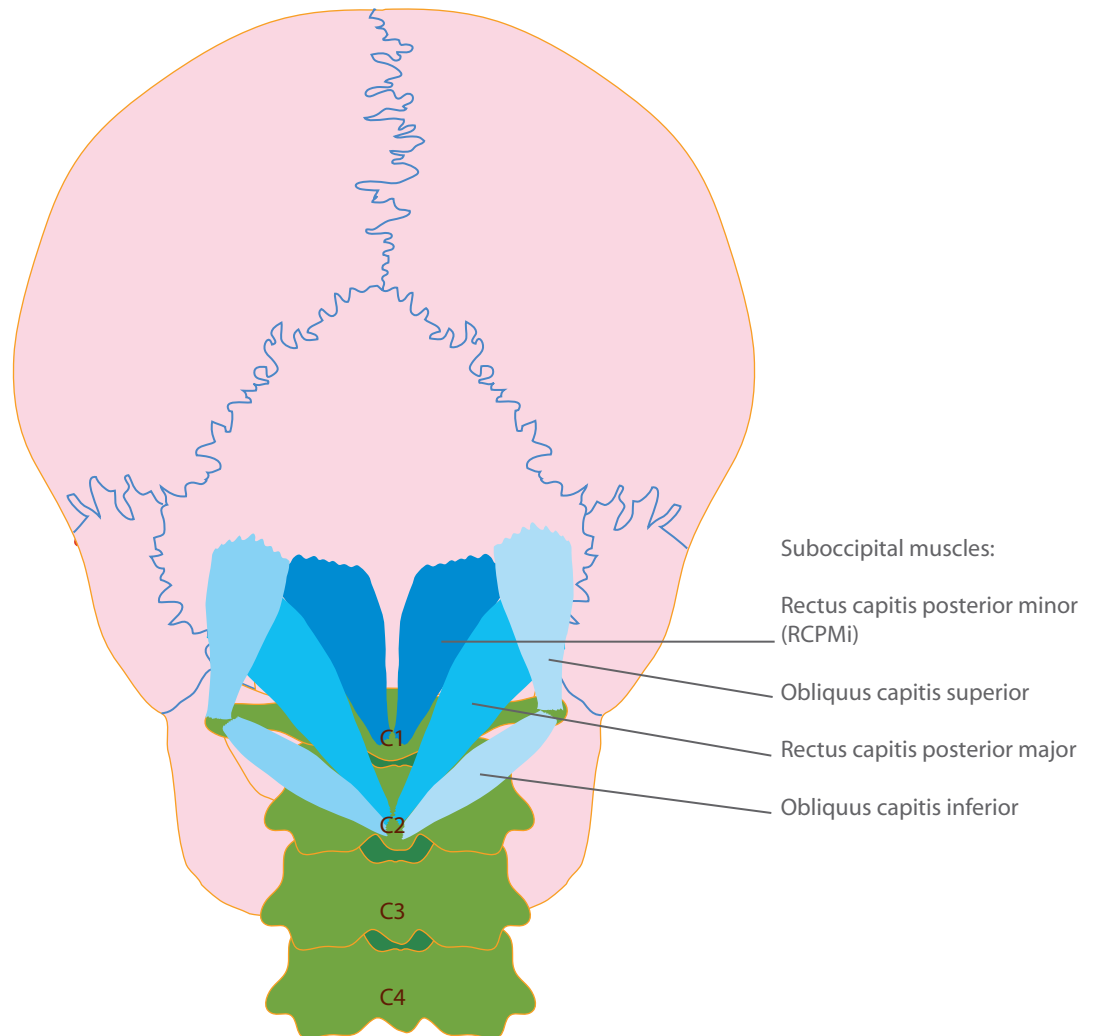


Figure 2. Suboccipital muscles



Posterior view of the cranium, upper 4 cervical spinal segments (C1-C4) and suboccipital muscles. The muscles that are normally on top of the suboccipital muscles have been removed.