

Figure 3. The Myodural Bridge.

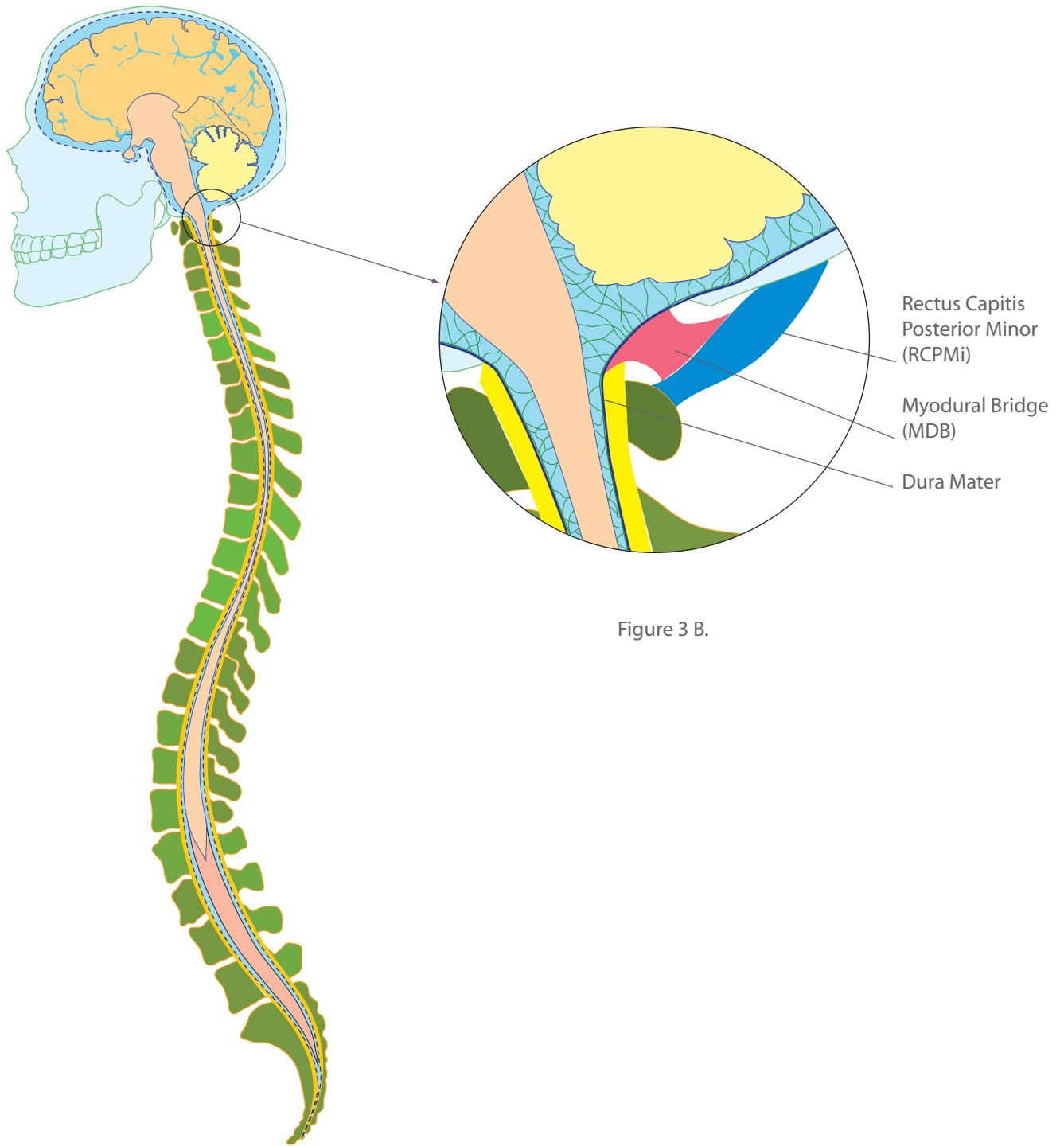


Figure 3 A.

Figure 3 B.

Figure 3 A. Mid-Sagittal section of the cranosacral system membrane layers as a dashed blue line surrounding the brain and spinal cord.

Figure 3 B. Enlarged section showing the Myodural Bridge (MDB) attached to the Rectus capitis posterior minor (RCPMi) muscle and the dura mater.