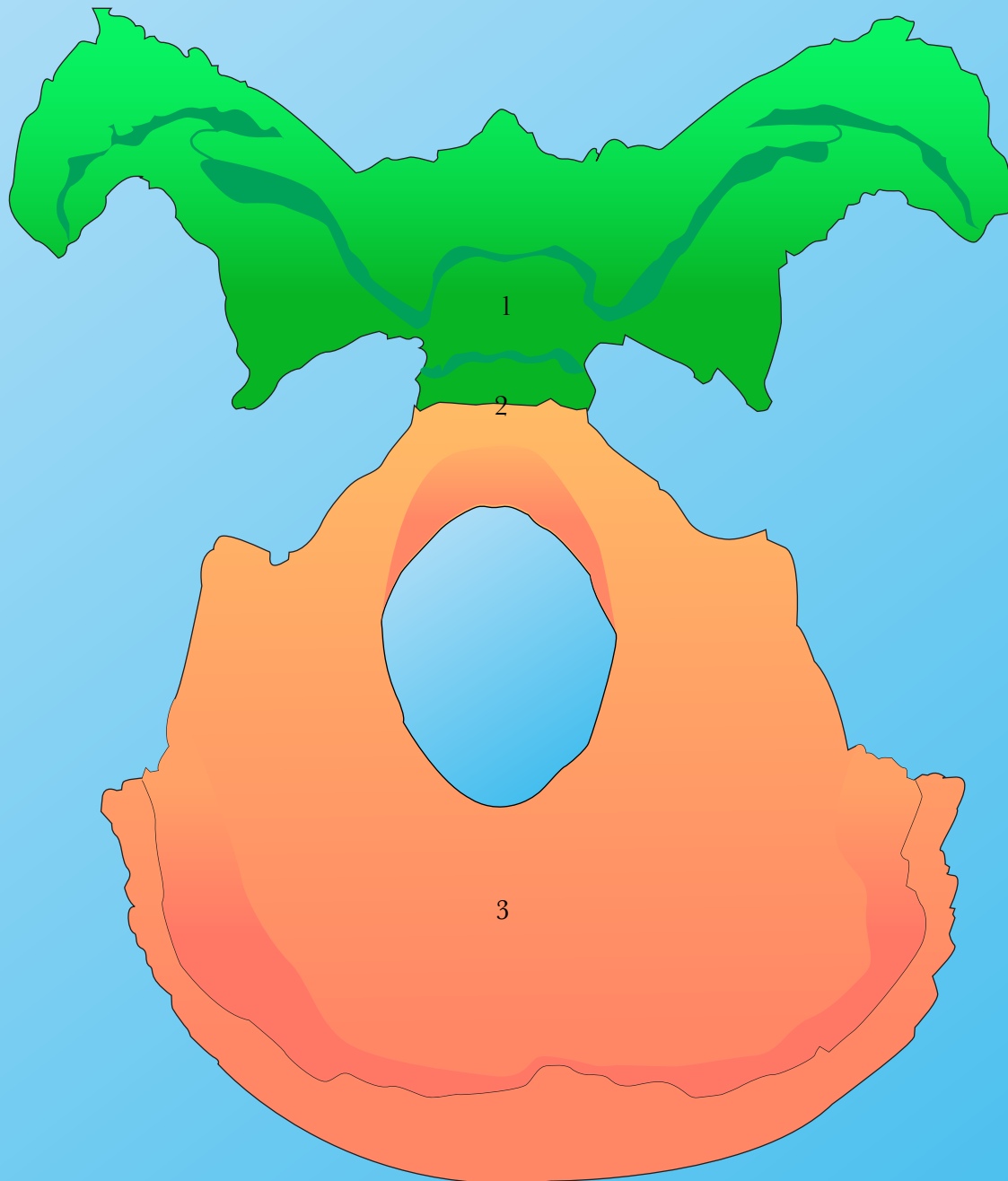


Sphenoid, Occiput and Sphenobasilar Symphysis



View of the sphenoid and the occiput.

The sphenoid and occiput have been removed from the cranium and placed in their normal articulation. The view is from above as if standing at the top of the head looking down upon them.

1. Sphenoid
2. Sphenobasilar Symphysis (SBS)
3. Occiput